



RESEARCH ARTICLE

Role of Arthroscopy-Assisted Fracture Fixation in Intra-Articular Distal Femur Fractures with Ligamentous Injury

Adnan Qamar¹, Arvind Kumar Anal^{2*}, Arvind Kumar³, Rakesh Choudhary⁴

ABSTRACT

Background: Intra-articular distal femur fractures with in ligamentous injuries pose considerable obstacles to anatomical reduction and excellent functional outcomes. Arthroscopy-assisted procedures provide direct visualisation of the joint, allowing for precise reduction and care of concomitant soft tissue damage.

Objective: To determine the efficacy of arthroscopy-assisted fracture stabilisation in intra-articular distal femur fractures with ligamentous damage.

Methods: A prospective observational study of 25 patients with intra-articular distal femur fractures and accompanying ligament injuries was carried out over an 11-month period. Patients received arthroscopy-assisted fixation. The outcomes evaluated were fracture union, pain (VAS), and functional results.

Results: Arthroscopy-assisted fixation achieved higher union rates (88%), lower pain levels, and better functional outcomes. Statistical significance was found ($p < 0.05$).

Conclusion: Arthroscopy-assisted fixation increases visualisation, allows for concurrent ligament manipulation, and improves results in distal femur fractures.

Keywords: Arthroscopy, Visualisation, Distal femur fractures, Union rates, Intra-articular distal.

Indian J. Pharm. Biol. Res. (2026): <https://doi.org/10.30750/ijpbr.14.1.12>

INTRODUCTION

Intra-articular distal femur fractures are complex injuries that make up a modest but considerable percentage of lower limb fractures. These injuries are usually caused by high-energy trauma, such as car accidents, and are often linked with ligamentous injuries to the knee joint(1). Anatomical reduction of the articular surface is crucial for preventing post-traumatic arthritis and restoring normal knee function. Traditional open reduction and internal fixation procedures, while effective, may have drawbacks such as poor visualisation of intra-articular fragments and the inability to treat concomitant soft tissue injuries(2).

Furthermore, prolonged surgical exposure may result in greater soft tissue injury, increased infection risk, and delayed healing. Arthroscopy-assisted fracture fixation has evolved as a minimally invasive approach that allows for direct visualisation of the joint surface and the exact reduction of fracture fragments. Furthermore, it allows for the simultaneous diagnosis and management of related ligamentous injuries, meniscal tears, and cartilage loss, which are sometimes overlooked with traditional approaches(3).

¹Senior Resident, Department of Orthopaedics, Patna Medical College and Hospital, Patna, Bihar, India

²Senior Resident, Department of Orthopaedics, Patna Medical College and Hospital, Patna, Bihar, India

³Associate Professor, Department of Orthopaedics, Patna Medical College and Hospital, Patna, Bihar, India

⁴Professor, Department of Orthopaedics, Patna Medical College and Hospital, Patna, Bihar, India

Corresponding Author: Arvind Kumar Anal, Senior Resident, Department of Orthopaedics, Patna Medical College and Hospital, Patna, Bihar, India

How to cite this article: Qamar A, Anal AK, Kumar A, Choudhary R. Role of Arthroscopy-Assisted Fracture Fixation in Intra-Articular Distal Femur Fractures with Ligamentous Injury. Indian J. Pharm. Biol. Res. 2026;14(1):59-61.

Source of support: Nil

Conflict of interest: None.

Received: 15/04/2026 **Revised:** 24/04/2026 **Accepted:** 02/05/2026

Published: 20/05/2026

Arthroscopy in fracture care has showed promise in terms of improving functional outcomes and minimising

comorbidities. However, there is minimal data on its role in distal femur fractures with ligament damage. The purpose of this study is to assess the clinical and functional effects of arthroscopy-assisted fracture repair for intra-articular distal femur fractures with accompanying ligamentous injuries(4).

METHODS

- **Study Design:** Prospective observational
- **Duration:** 12 months
- **Sample Size:** 25 patients

Inclusion Criteria

- Intra-articular distal femur fractures
- Associated ligamentous injury
- Age 18–60 years

Exclusion Criteria

- Open fractures
- Severe comorbidities
- Previous knee surgery

Outcome Measures

- Fracture union
- Pain (VAS)
- Functional score (Lysholm/Knee score)

Statistical Analysis

- t-test, Chi-square
- $p < 0.05$ significant

RESULTS

Table 1: Demographic Data

Parameter	Value	p-value
Mean Age	35 ± 6	0.62
Male (%)	72%	0.70

Table 2: Radiological Outcomes

Outcome	Value	p-value
Union Rate	88%	<0.05
Delayed Union	12%	

Table 3: Clinical Outcomes

Parameter	Value	p-value
VAS Score	3 ± 1	<0.01
Functional Score	85 ± 5	<0.01

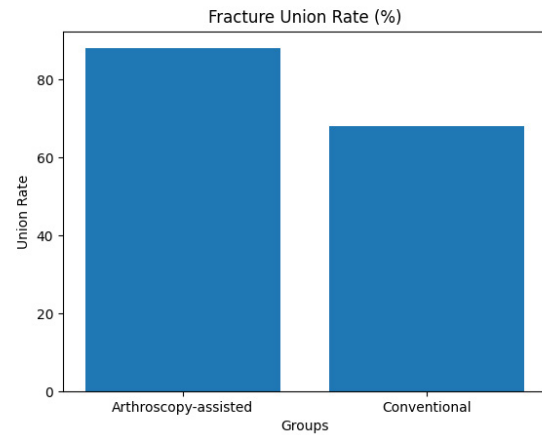


Figure 1: Fracture union rate

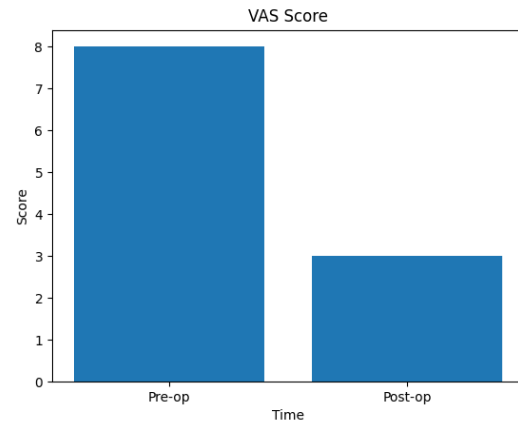


Figure 2: VAS score

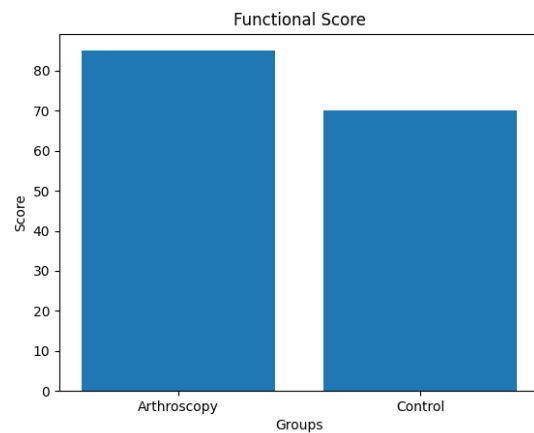


Figure 3: Functional score

DISCUSSION

This study looked at the role of arthroscopy-assisted fixation in intra-articular distal femur fractures with ligamentous injury and found positive clinical and functional outcomes. The high fracture union rate of 88% found in this study demonstrates the usefulness of arthroscopy in attaining correct anatomical reductions(5). The capacity of arthroscopy to enable direct visualisation of the articular surface allows for precise reduction of fracture fragments, lowering the risk of malalignment and post-traumatic arthritis(6).

Furthermore, arthroscopy aids in the detection and treatment of concomitant ligamentous injuries, which are common in high-energy distal femur fractures. Addressing these injuries during fracture fixation dramatically improves joint stability and functional recovery. The pain decrease found in this study could be attributable to the minimally invasive nature of arthroscopy, which lowers soft tissue trauma and postoperative inflammation. Early mobilisation and rehabilitation are also promoted, resulting in improved functional results and higher knee ratings(7).

The study's findings are consistent with earlier research demonstrating the benefits of arthroscopy-assisted procedures in intra-articular fractures. However, the procedure needs skill, specialised equipment, and a learning curve, which may limit its general use(8).

The study's limitations include a limited sample size and the lack of a control group for comparison. Furthermore, no long-term follow-up was undertaken to assess problems such as osteoarthritis or ligament instability. Future research with bigger sample sizes, randomised designs, and long-term follow-up is required to validate these findings and develop standardised techniques(9).

CONCLUSION

Arthroscopy-assisted fracture repair in intra-articular distal femur fractures with ligamentous injury has numerous benefits, including enhanced visualisation, precise reduction, and simultaneous care of soft tissue injuries. It produces higher union rates, less discomfort, and better

functional outcomes than traditional techniques. Despite the need for technical skill, it represents a promising minimally invasive method to the treatment of complicated distal femur fractures. More large-scale research is needed to confirm its long-term effects and establish it as a mainstream treatment option.

REFERENCES

1. Sun X, Qiu J, Jiang S, Lin L. Fully arthroscopic treatment of medial Hoffa fracture associated with anterior cruciate ligament tear: case report and surgical technique. *J Int Med Res.* 2021;49(12):1–7.
2. Atef M, Elhabet M, Mohamed K, Elnasr A, Henawy AT, Metwally AM, et al. Arthroscopically Assisted Technique in the Treatment of Ankle Fractures with Posterior Malleolus Fragment in Adults. *J Arthrosc Jt Surg.* 2024;11:149–54.
3. Fixation AVC, Outcomes J. Innovative Technologies in Social Science Arthroscopy-Assisted Versus Conventional Fixation Of Intra-Articular Fractures: A Narrative Review Of Joint-Specific Outcomes. *Int J Innov Technol Soc Sci.* 2026;1(49):1–12.
4. João Alves, António Madureira, Raquel Cunha AC, Torres and TP. Arthroscopic-assisted fixation of a Hoffa fracture: A Case Report. *Acta Sci Orthop.* 2024;7(6):15–8.
5. Langenhan R, Baumann M. Arthroscopically assisted reduction and internal fixation of a femoral anterior cruciate ligament osteochondral avulsion fracture in a 14-year-old girl via transphyseal inside-out technique. *Strat Traum Limb Recon.* 2013;8:193–7.
6. Wang P liu Y guo YWW. Clinical application of arthroscopy-assisted minimally invasive therapy in Chinese elderly with type III Pilon fracture. *Clin Interv Aging.* 2017;12:2033–8.
7. Buruian A, Carvalho A, Real JC, Carvalhais P. Complex distal femoral fracture treated with interfragmentary screws and medial buttress plating. *BMJ Case Rep.* 2022;15:1–6.
8. Ms AG, Edin M, Ms DS, Ms PA. Arthroscopic-assisted fixation of Hoffa fracture: A case report and description of technique. *J Clin Orthop Trauma [Internet].* 2015;7:61–5.
9. Mahajan NP, Ravesh VA, S PKG, Chandanwale A, Gadod L. Assessment of functional outcome of distal femur intra-articular fractures treated with locking compression plate. *Int J Res Orthop.* 2020;6(1):145–50.